

PATIENT PRESENTING CLINICAL SIGNS

Bucky Gazo History: 3-day duration of anorexia, vomiting and diarrhea.

SPECIES Physical Examination: N/A.

Canine Urinalysis: N/A.

CBC: N/A.

BREED Serum Biochemistry: N/A.

Cocker Spaniel Radiographic Findings: N/A.

SEX

Male

AGE

14 years

WEIGHT

20.1 #

INTERPRETED BY

Remo Lobetti, BVSc,
MMedVet (Med), PhD, Dipl.
ECVIM

ULTRASONOGRAPHIC EXAMINATION OF THE ABDOMEN

Urinary System

Full urinary bladder with a normal thickness and appearance of the wall. Normal anechoic urine with no sediment or uroliths evident.

Normal trigone area, proximal urethra, and iliac blood vessels.

Normal iliac lymph nodes. Ureters not visualized.

Normal renal size (right 4.4 cm) with increased echogenic appearance, some loss of cortico-medullary differentiation, normal pelvis, and regular capsule of the left kidney. Irregular capsule of the right kidney. Focal medullary nodule in the cranial pole of the left kidney.

Adrenal Glands

Normal shape, echogenic appearance, size, and position. Left 2.2 cm, right 1.9 x 0.7 cm.

Spleen

Normal size and echogenic appearance. Smooth homogenous parenchyma, regular capsule, and normal vasculature. No evidence of inflammatory, neoplastic, infarction, or infiltrative changes noted.

Liver

Normal size, echogenic appearance, and portal markings. No nodules or masses evident. Small gall bladder containing normal anechoic bile. Normal appearance and thickness of the gall bladder wall. Normal bile duct.

Gastrointestinal

Normal appearance of the duodenum, small intestine, ileo-cecal junction, and colon with no loss of layering, normal wall thickness, and no loss of layering or distension of the lumen. Normal appearance of the gastric wall. Large amount of fluid within the stomach. Small hyperechogenic foreign body (2.2 cm) within the fundus of the stomach.

INVOICE

302529

DATE

8/26/21

IMAGING PERFORMED BY

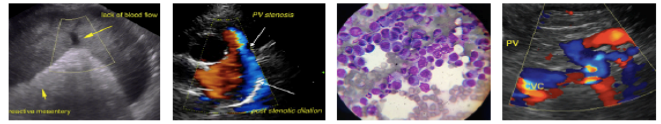
Dr Paul Kim

HOSPITAL NAME

Ridgefield Park Animal
Hospital

REFERRING VET

Dr Paul Kim



PATIENT *Pancreas*

Bucky Gazo Normal size (0.84 and 0.86 cm) with a diffuse hypoechogenic appearance. Irregular capsule. Hyperechogenic appearance of the mesentery and fat surrounding the pancreas.

SPECIES *Free Abdomen*

Canine No mesenteric lymphadenomegaly.
No ascites.

BREED

Cocker Spaniel

ULTRASONOGRAPHIC FINDINGS

Primary Findings:

- Pancreatitis.
- Fluid-filled stomach with possible foreign body.

SEX

Male

AGE

14 years

Secondary Findings:

- Age-related renal changes vs renal disease.
- Renal nodule?

WEIGHT

20.1 #

INTERPRETATION OF THE FINDINGS & FURTHER RECOMMENDATIONS

INTERPRETED BY

Remo Lobetti, BVSc,
MMedVet (Med), PhD, Dipl.
ECVIM

The appearance of the pancreas is typical for pancreatitis with neoplasia a less likely differential diagnosis.

Although the fluid-filled stomach is most likely associated with the pancreatitis, foreign body needs to be considered.

IMAGING PERFORMED BY

Dr Paul Kim

The appearance of the kidneys is consistent with age-related changes with chronic kidney disease, a differential diagnosis. Etiologies for the renal nodule would be incidental adenoma, neoplasia, granuloma, hematoma, and organized abscess.

HOSPITAL NAME

Ridgefield Park Animal
Hospital

Further assessment would be urinalysis, urine culture, renal function (urea, creatinine, SDMA), cPL/PSL, and possibly FNA cytology of the pancreas and renal nodule. Ultrasound monitoring of the stomach, pancreas, and renal nodule would also be recommended.

REFERRING VET

Dr Paul Kim

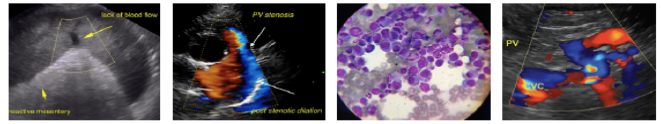
Specific therapy would be dependent on an etiological diagnosis. Symptomatic management would be fluid therapy as needed, anti-emetics (maropitant), opioid analgesics, and enteric binders.

INVOICE

302529

DATE

8/26/21



PATIENT

Bucky Gazo

SPECIES

Canine

BREED

Cocker Spaniel

SEX

Male

AGE

14 years

WEIGHT

20.1 #

INTERPRETED BY

Remo Lobetti, BVSc,
MMedVet (Med), PhD, Dipl.
ECVIM

IMAGING PERFORMED BY

Dr Paul Kim

HOSPITAL NAME

Ridgefield Park Animal
Hospital

REFERRING VET

Dr Paul Kim

INVOICE

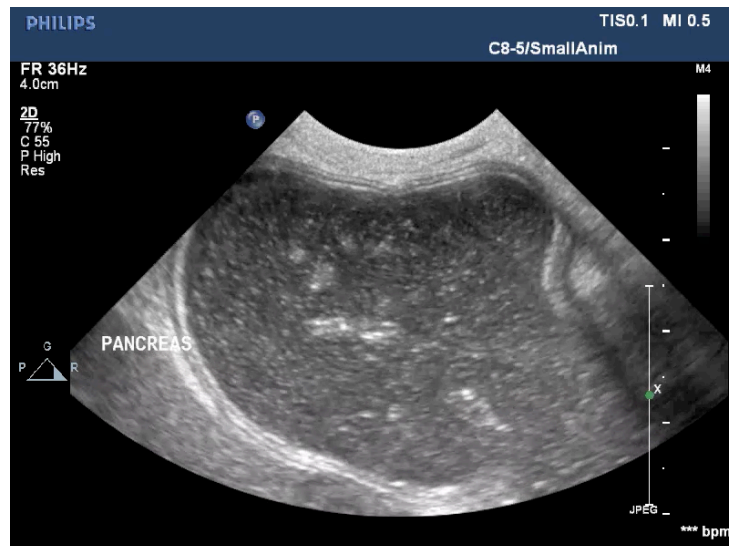
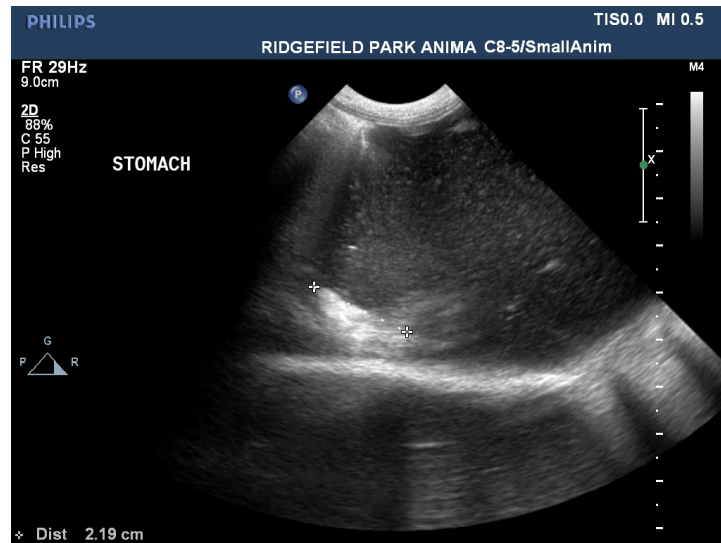
302529

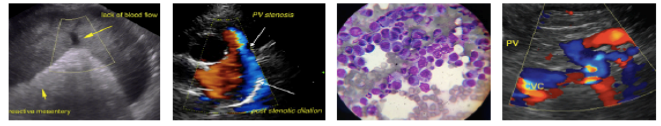
DATE

8/26/21

IMAGES

Stomach





PATIENT

Bucky Gazo

SPECIES

Canine

BREED

Cocker Spaniel

SEX

Male

AGE

14 years

WEIGHT

20.1 #

INTERPRETED BY

Remo Lobetti, BVSc,
MMedVet (Med), PhD, Dipl.
ECVIM

IMAGING PERFORMED BY

Dr Paul Kim

HOSPITAL NAME

Ridgefield Park Animal
Hospital

REFERRING VET

Dr Paul Kim

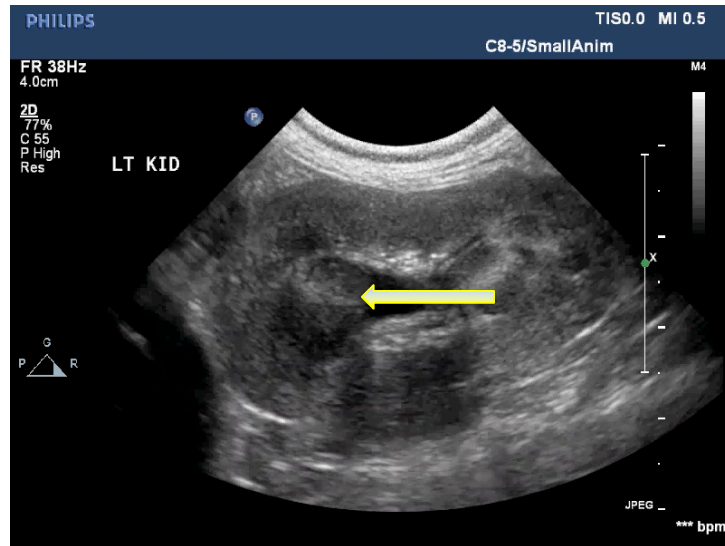
INVOICE

302529

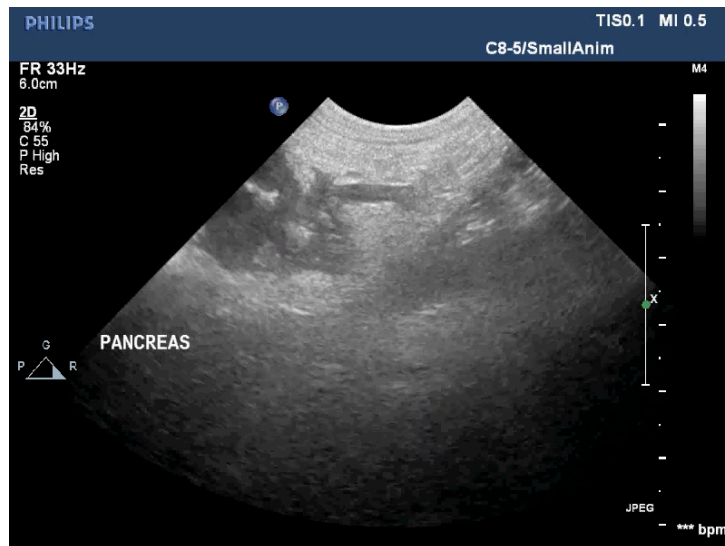
DATE

8/26/21

Left kidney (renal nodule arrow)



Pancreas



The information and recommendations provided are based on the images presented by the referring veterinarian. No evaluation can be communicated regarding pathology that was not visible in the image/video clips provided.

Thank you for this referral. If the clinical or image interpretation does not parallel your findings or if I can be of any further assistance, please contact me.

Remo Lobetti, BVSc, MMedVet (Med), PhD, Dipl. ECVIM (Internal Medicine)
rlobetti@mweb.co.za